

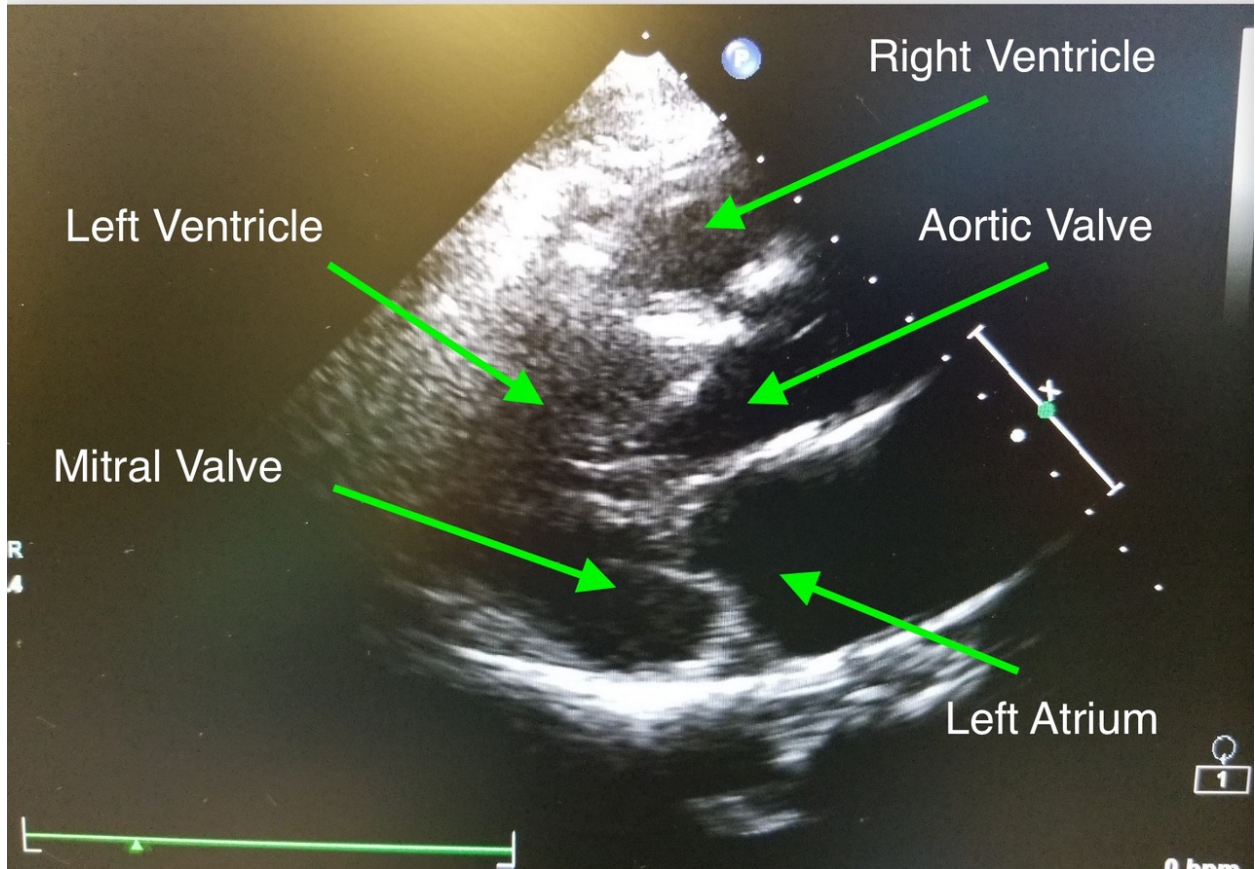Figure 1: Transthoracic echocardiogram image of the parasternal long axis view taken after combined spinal-epidural placement (CSE)

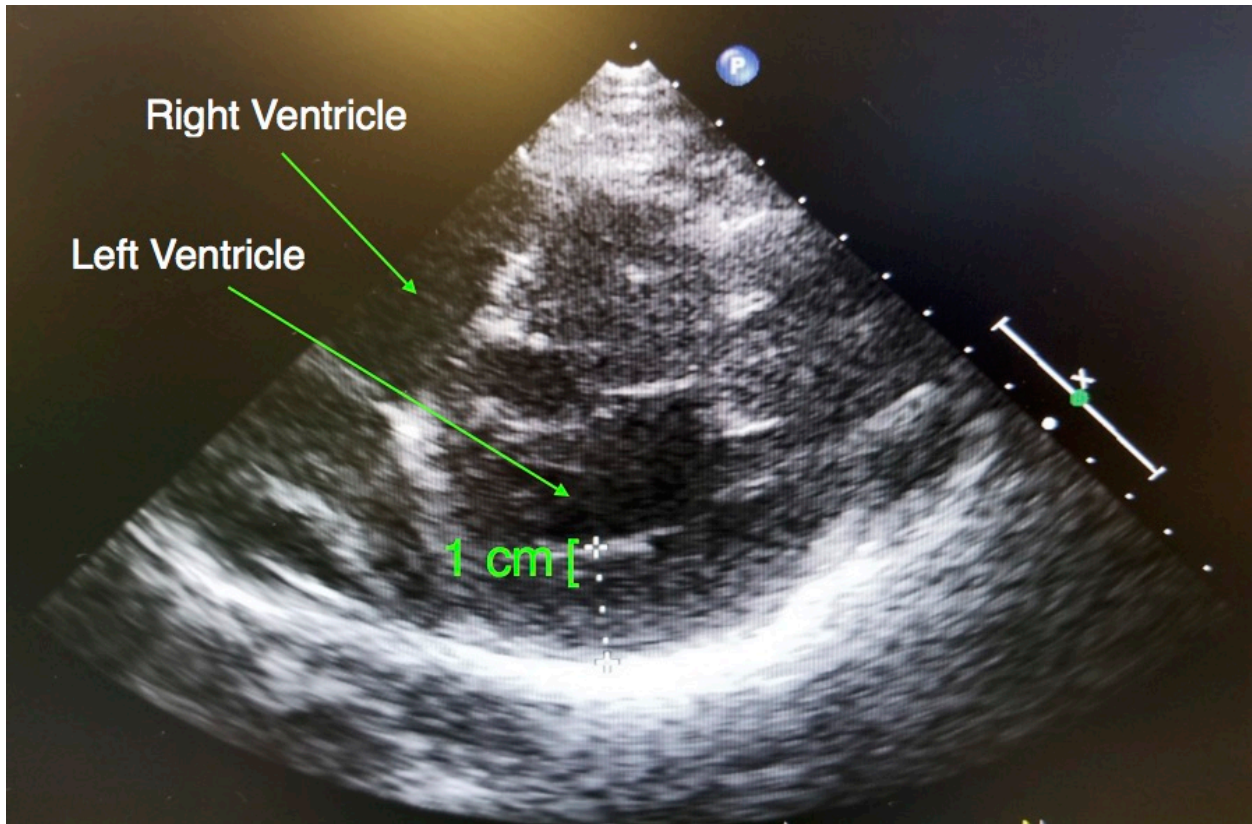


Figure 2: Transthoracic echocardiogram image of the parasternal short axis view taken after CSE placement. Left ventricular wall was measured and was noted to be > 30mm in thickness